

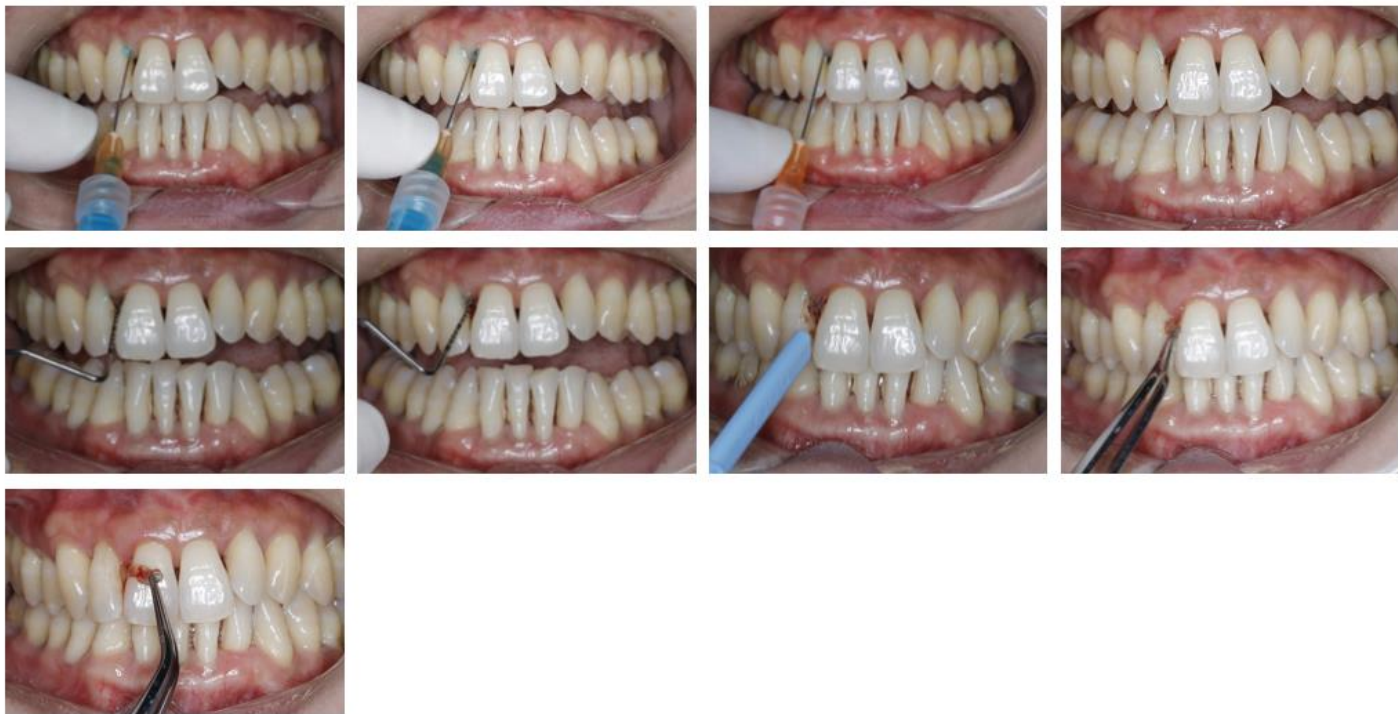

**Italian quality and innovation  
for oral health**

**Ubigel Inperio  
User guide and  
Clinical case studies**

## 1. How to use Ubigel Inperio:

The product consists of two gels designed for their sequential placement in the pockets periodontal. Both gels have low viscosity and polymerize when applied both. For placement under gingival, the product has a disposable cannula with hole of lateral exit about 2 mm from the tip of the cannula, which has a rounded design. After applying both gels the product assumes, almost instantly, a greater consistency.

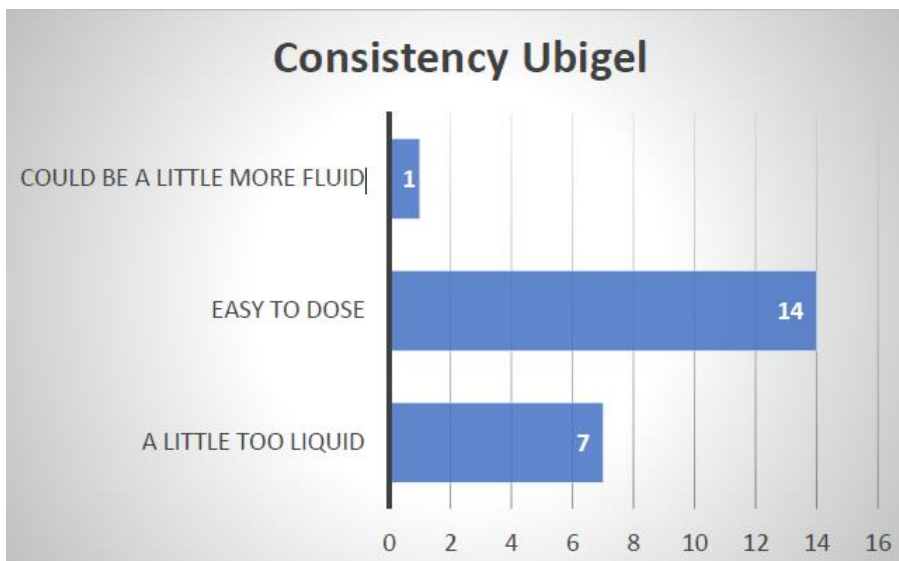


## 2. User test

An inquiry was conducted to evaluate the users experience of Ubigel Inperio. They received 22 responses from 42 test customers. Questions and answers are summarized in the chart below.

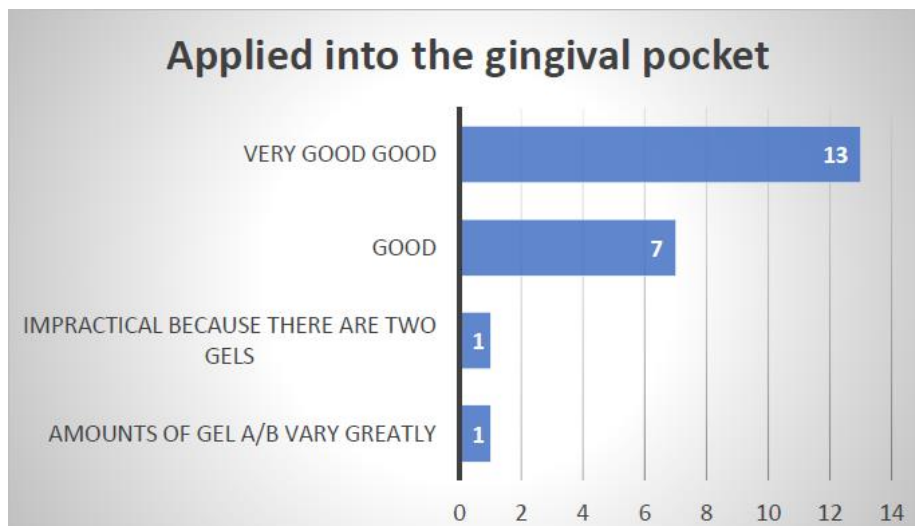
### Question 1:

How would you rate the consistency of Ubigel Inperio?



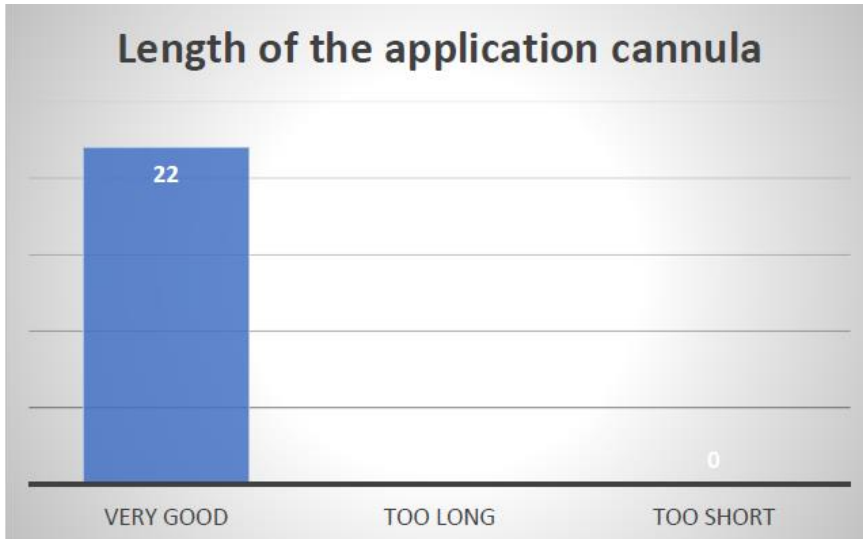
### Question 2:

How could Ubigel Inperio be applied into the gingival pocket?



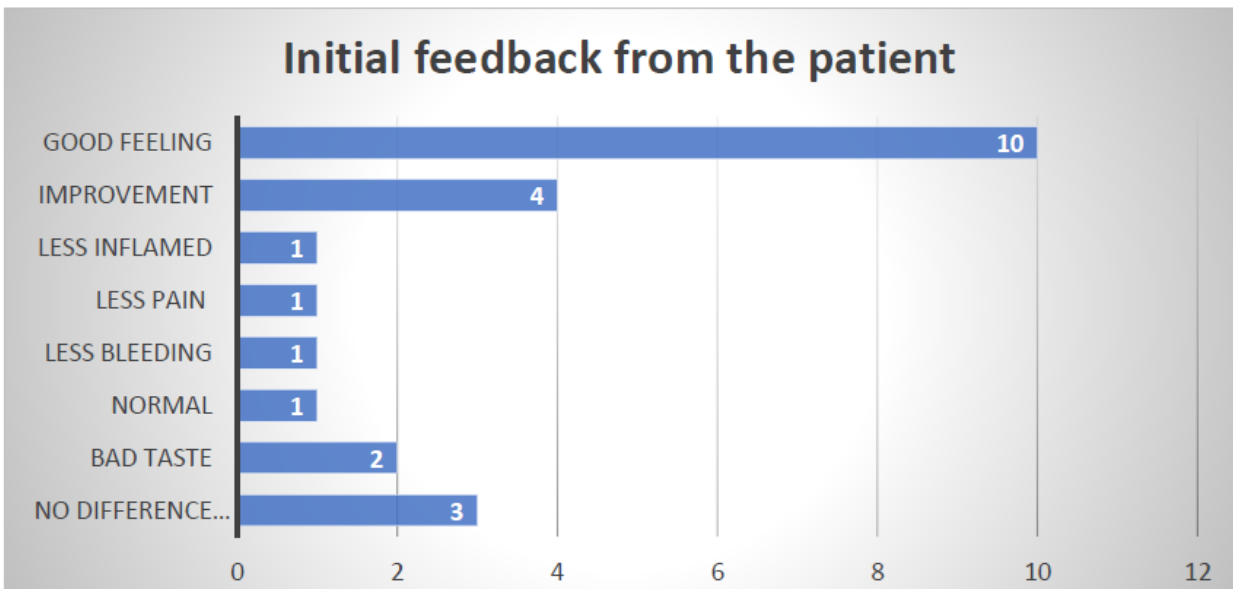
**Question 3:**

Is the length of the application cannula appropriate?



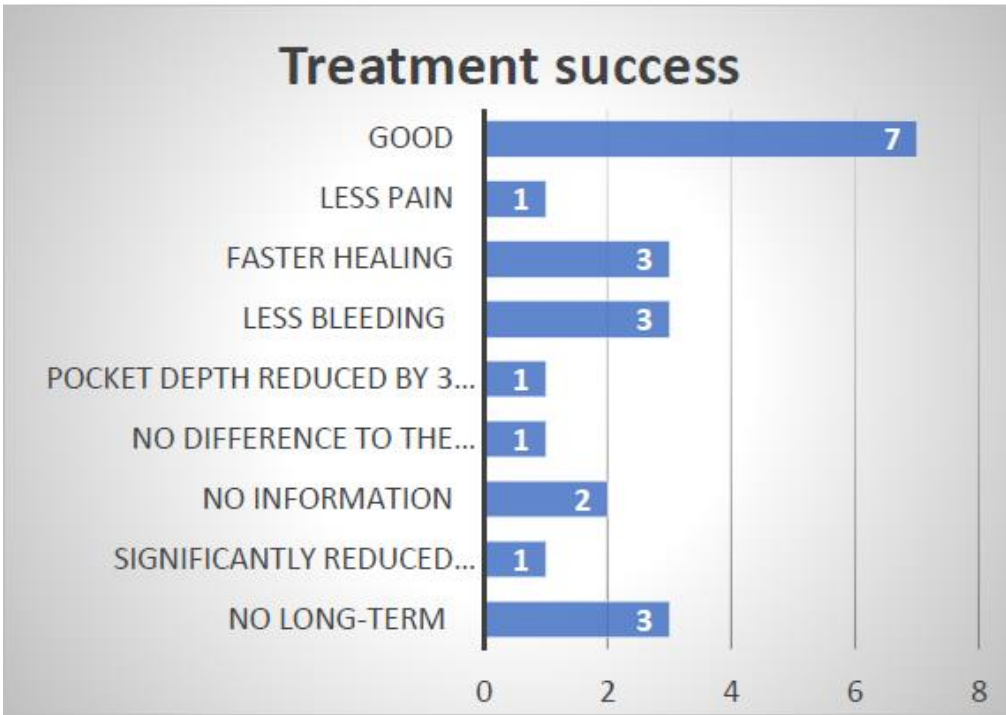
**Question 4:**

Initial feedback from the patient at the follow-up visit



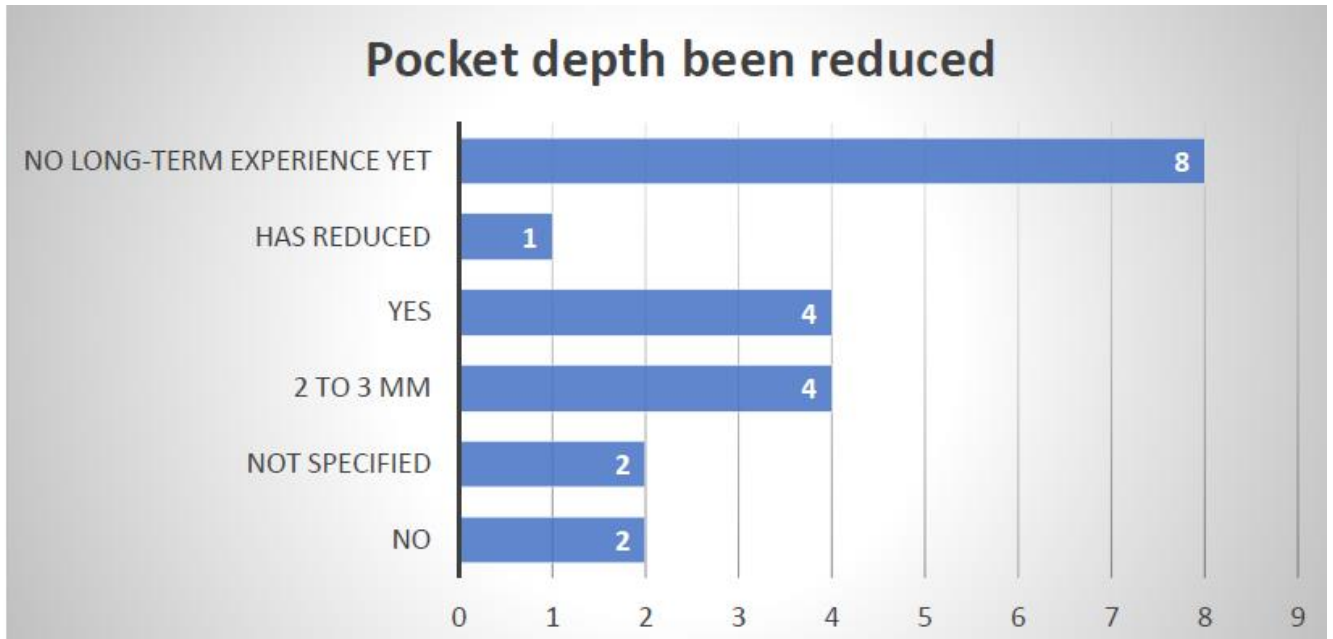
**Question 5:**

What positive effect did Ubigel Inperio have in treating the periodontitis?



**Question 6:**

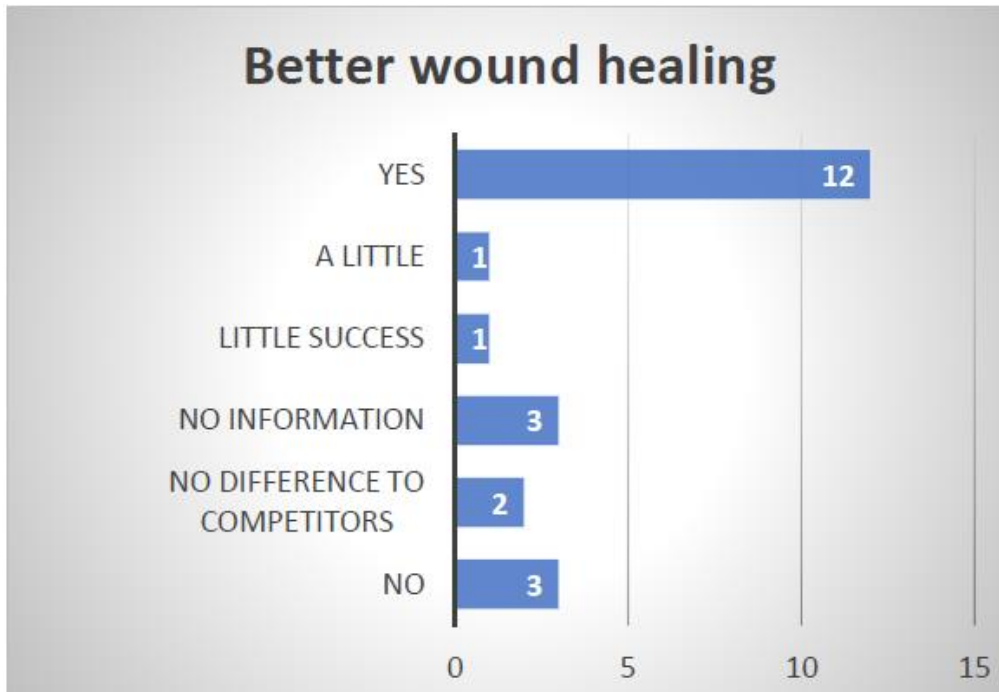
Has the pocket depth been reduced after treatment with Ubigel Inperio reduced?





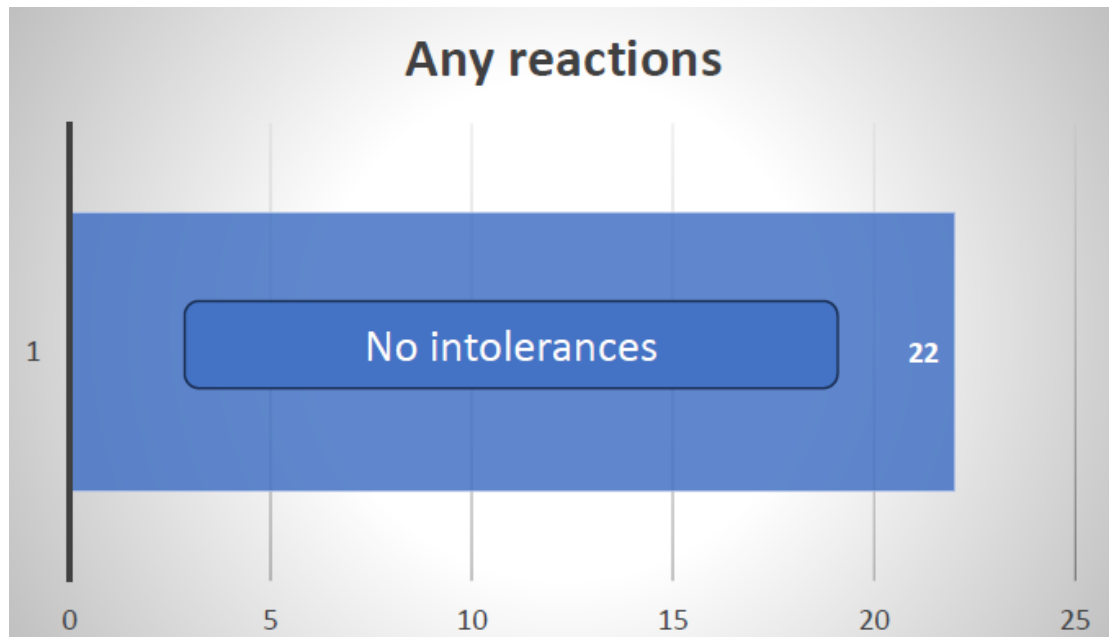
**Question 7:**

Did you notice better wound healing after treatment with Ubigel Inperio-shorter healing time?



**Question 8:**

Did any reactions occur during treatment with Ubigel Inperio e.g. intolerances?





## User test evidences:

Ubigel Inperio has been considered a medical device **easy to use** and good to apply in the gingival pocket: the cannula is length enough to ensure an appropriate application and the consistency is good.

After the first application the **patients experienced a good feeling**, Ubigel Inperio **has a good effect in the treatment of periodontitis**: in some cases the **pocket depth been reduced**, and in almost all patients involved in the test was noted **a better wound healing** after treatment with Ubigel Inperio and/or a shorter healing time.

In all the patients **no adverse reactions** was occurred.



### 3. Case studies

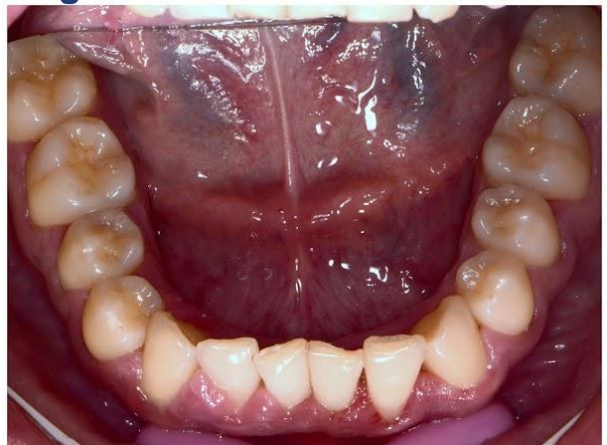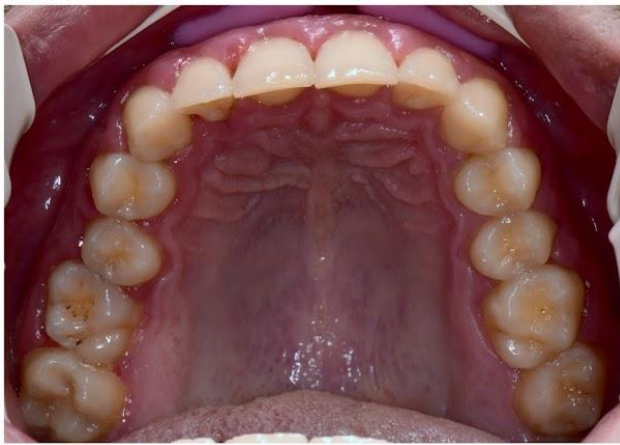Dr. Cristina Nicolau reported 3 clinical case studied on patients with periodontitis at the first stages.

#### Case 1:

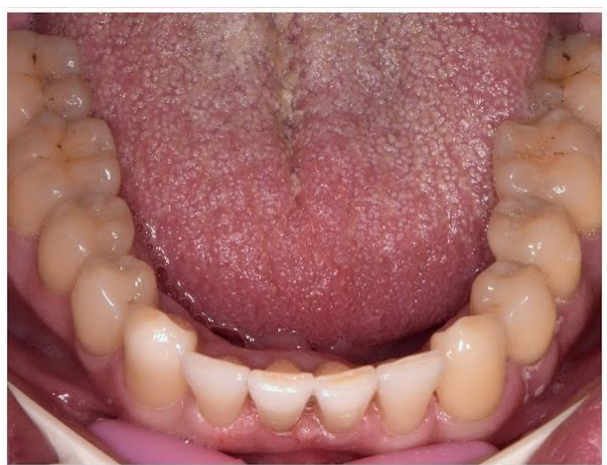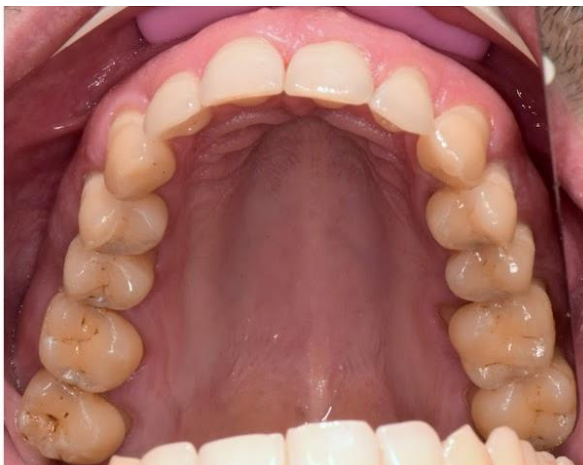39-year-old patient, superficial chronic marginal periodontitis.

Treatment: subgingival scaling, 2 applications of Ubigel at a 2-week interval.  
Initial photos and after a difference of 1 month.

**Before Ubigel**



**After Ubigel**





## Case 2:

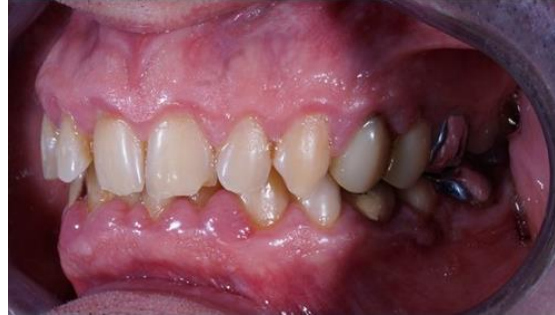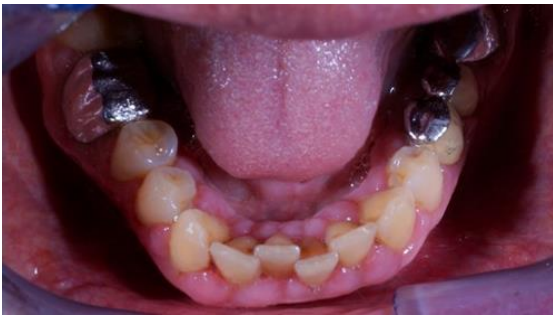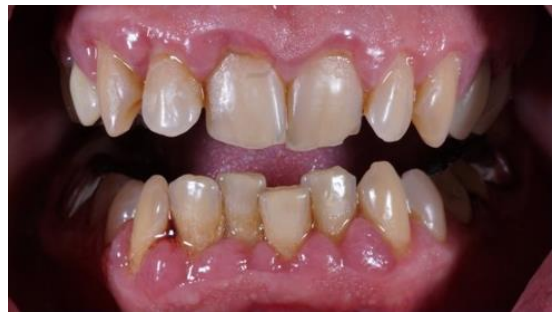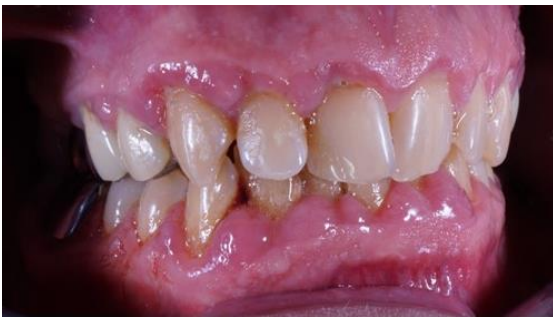47-year-old patient, drug-induced hyperplasia Treatment.

Session 1: subgingival scaling and Ubigel applications.

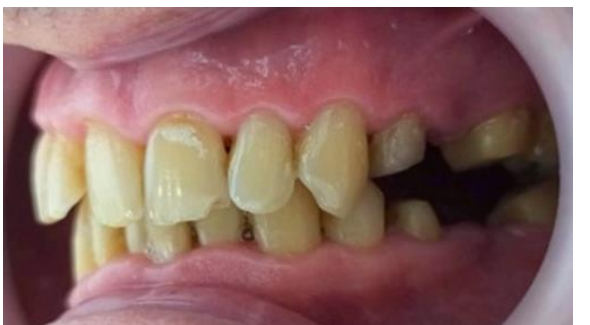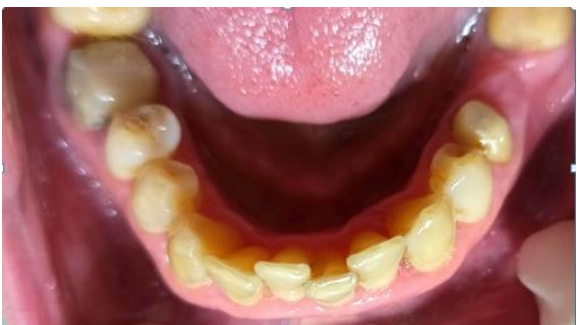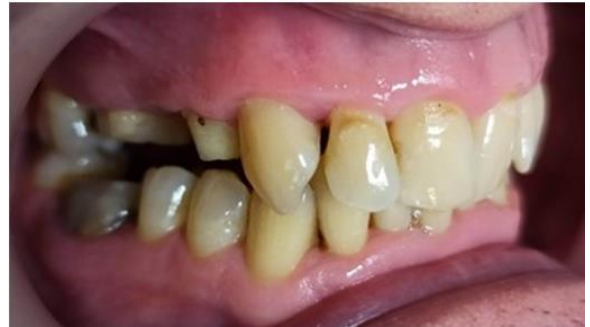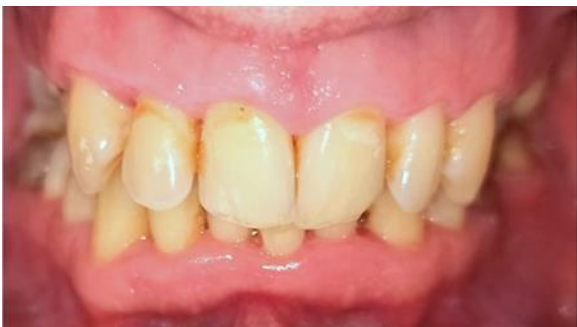Session 2: Ubigel applications.

Photos at 3 months from the start of treatment

### Before Ubigel



### After Ubigel



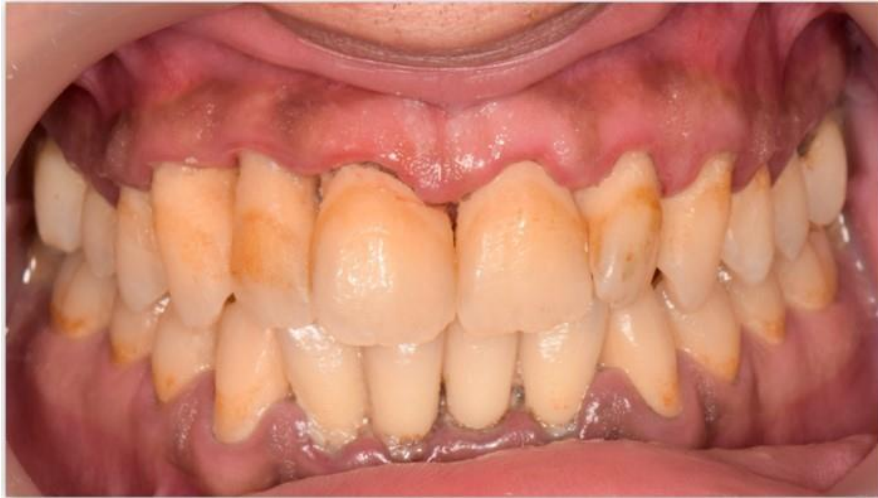### Case 3:

30-year-old patient.

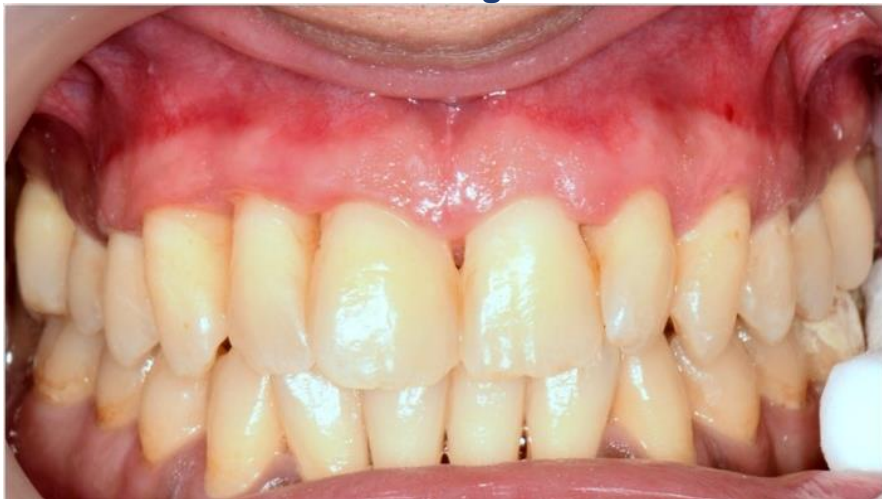Treatment: subgingival scaling and one application of Ubigel.

Photos after a difference of 1 month

**Before Ubigel**



**After Ubigel**



## Conclusions:

The clinical situation of patients who benefited from adjunctive Ubigel treatment is visibly improved after just one application. Ubigel is useful in gingivitis or in correlation with periodontal therapy. The sealing gel for periodontal pockets is better applied when the mucosa is dry; otherwise, it is a liquid gel that attaches with difficulty to the free gingival margin.

**Dr. Cristina Nicolau**  
Bucherst OnDental

 +40 755416612

 [contact@ondental.ro](mailto:contact@ondental.ro)





## 4. Ubigel Inperio clinical trial:

A clinical trial was conducted by Dr. David Rizzo. A sample of 70 patients was selected equally divided between the two sexes (the female sample was not in the pre or post-menstrual phase), with the following common anamnesis:

- Non smoking
- not in drug therapy
- no systemic disease
- Mediterranean diet
- Complete and natural dental formula
- Normotrophic mucosa
- Normotrophic language
- Gingivitis
- Periodontal probe between 2 and 4 mm
- Plaque index 2-3
- Bleeding at the poll

All patients in the study were given a periodontal chart during the first visit and dental hygiene was then carried out using ultrasound equipment, manual scaling, air flow, Polishing with prophylactic paste and explanation of home oral hygiene manoeuvres.

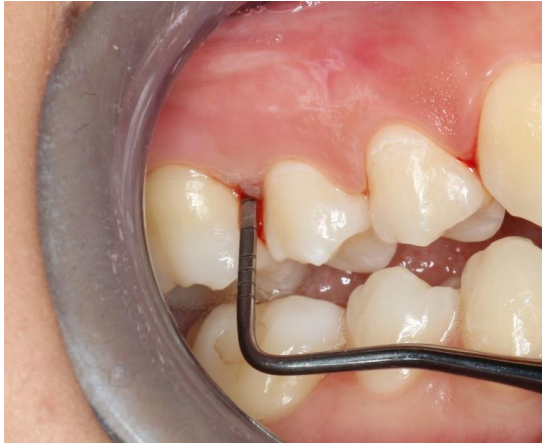After 20 days, patients were revisited and their periodontal status was re-evaluated.

Of the 70 initial patients, only 63 were returned to control and of these, 31 still had periodontal probing between 2 and 4 mm, probing bleeding and tenderness. Fourteen men and 14 women were selected to be treated with Ubigel Inperio.

Before the application to patients, a further ultrasound hygiene session was performed, at the end of which Ubigel Inperio was applied. At the end of the treatment, it was prescribed not to drink and eat for at least 1 hour, not to brush for the next 12 hours and not to use dental floss for 15 days, the second application of Ubigel was scheduled for 7 days. At the second appointment, 70% of patients reported an improvement in their gingival status, no bleeding during brushing and no more pain during the same. After the second session, the same precautions as for the first session were prescribed. Patients were therefore assigned a follow-up between 20 and 30 days after the second application of Ubigel Inperio

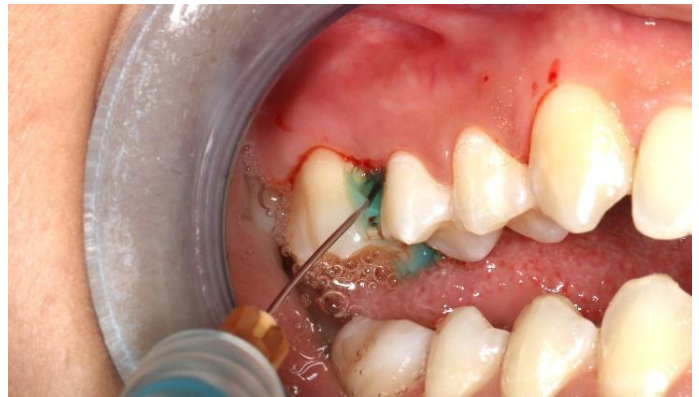
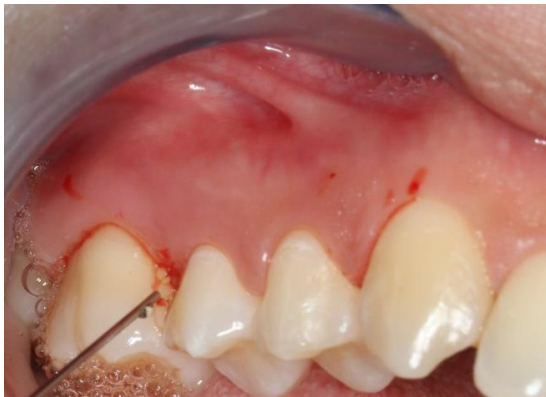
At the check-up we reassessed the periodontal status, from which it was concluded that, out of 28 patients, 20 had no more periodontal examination and no bleeding, 5 presented pockets of 1 mm in some dental elements and no bleeding, and only 3 had a 2 to 3 mm depth of bleeding.

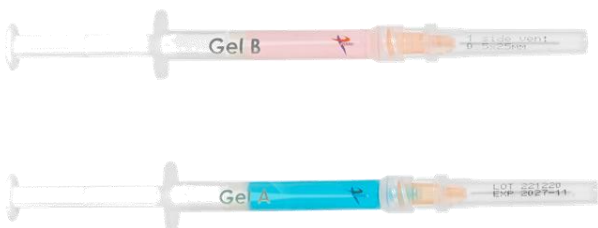
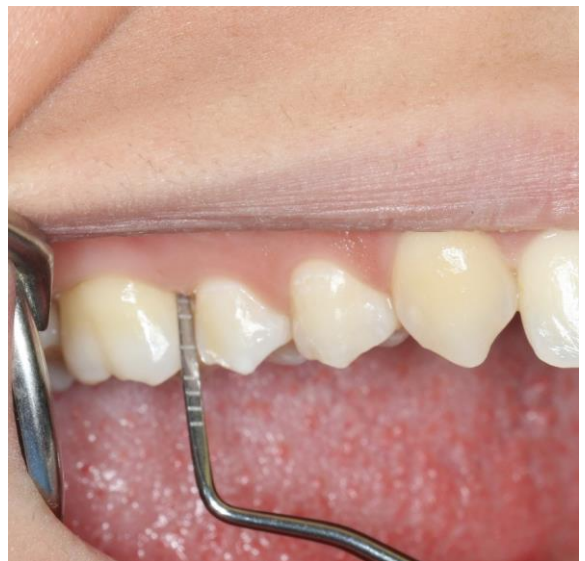
Picture A survey pre treatment 7 days after the professional hygiene is 3 mm with presence of gingival bleeding.

Pictures B and C Ubigel Inperio treatment



Picture D survey after 21 days of treatment with Ubigel Inperio: pokes deep is less than 2mm and no bleeding gum.





## Conclusions:

We can state that in all patients with gingivitis and therefore with pockets smaller than or equal to 3 mm it produced a partial or total regression of the probing depth, a consequence of the recovery of the epithelial attachment and absence of bleeding, thanks to the "reclamation " bacterial carried out by Ubigel Inperio, inside the gum pocket. The patients interviewed a week after the first application reported having noticed an improvement in their gum conditions, less bleeding, less pain when brushing and less redness, starting from the following days, while usually with professional hygiene alone the recovery times they are longer.

### Dr. David Rizzo

Studio Dentistico dott. David Rizzo, Messina (Italy)

+ 39 090 232 0241

dr.davidrizzo@libero.it

